

TESTICULAR DEGENERATION DUE TO INADEQUATE VITAMIN  
A IN CASES WHERE E IS ADEQUATE

BY

HERBERT M. EVANS

*From the Institute of Experimental Biology, University of California*




Make

B

58  
21

REPRINTED FROM THE AMERICAN JOURNAL OF PHYSIOLOGY  
Vol. 99, No. 2, January, 1932



## TESTICULAR DEGENERATION DUE TO INADEQUATE VITAMIN A IN CASES WHERE E IS ADEQUATE<sup>1</sup>

HERBERT M. EVANS

*From the Institute of Experimental Biology, University of California*

Received for publication July 21, 1931

Somewhat over a year ago Mason<sup>2</sup>, to whom we are indebted for an excellent series of studies on the relation of the male gonads to various dietary regimes, reported the degeneration of the seminiferous epithelium in rats "fed purified diets adequate in all respects except for deficiency in vitamin A. Supplementing these diets with large amounts of vitamin E produced no protection against these changes." The present work, begun before the publication of Mason's results, will be regarded, we trust, as an adequate substantiation of his claim. It is presented, however, not merely because of differences in the diets and methods employed in the two researches, but primarily because of our attention to the question of adequacy of the amounts of vitamins A and E—a question unfortunately left open in the Mason work. It is certainly necessary, we believe, to provide a control group of animals fed adequate amounts of vitamin A as proof that the simultaneously administered E was adequate.

As a preliminary effort 12 animals were reared on an A-free diet<sup>3</sup> and 20 drops of wheat germ oil per day. A control group of 12 animals re-

<sup>1</sup> Aided by grants from the Committee for Research in Problems of Sex of the National Research Council and from the Bureau of Dairying of the United States Department of Agriculture. These funds have been generously augmented by the Board of Research and by the College of Agriculture of this University.

<sup>2</sup> Mason, Karl E., *Journal of Experimental Zoology*, 1930, lv, 101.

<sup>3</sup> Two diets low in vitamin A were used in this series—diets 411 and 421A. The composition of the two diets differed only in the type of casein used. Casein extracted with hot alcohol was used in diet 411 in place of the unextracted casein used in diet 421A. Animals on diet 421A exhibit symptoms of vitamin A deficiency later than those on diet 411 but in this experiment the administration of 20 drops of wheat germ oil obscured this difference and the results obtained from the two groups were essentially the same.

<i>Diet 411</i>		<i>Diet 421A</i>	
Casein (ext. with hot alcohol)	25.0	Casein (unextracted)	25.0
Cornstarch (cooked)	57.0	Cornstarch (cooked)	57.0
Yeast	8.0	Yeast	8.0
Lard (irradiated)	10.0	Lard (irradiated)	10.0
Salt mixture * 185	4.0	Salt mixture * 185	4.0

ceived the same diet supplemented with 20 drops of wheat germ oil and 2 drops of cod liver oil daily. Inasmuch as we can rescue any particular pregnancy in a female proven to be sterile from defective E by the simple conveyance of a single drop of wheat germ oil daily during the period of gestation, the reader will observe that the employment of 20 drops daily in our experiments with males furnished them a very great excess of E. We realize that the amounts of vitamin A in this high dosage of wheat germ oil were not inconsiderable but previous work in the rearing of females with these high amounts of wheat germ oil (20 drops daily) had demonstrated that they ultimately exhibited the characteristic sign of A deficiency (cornified cell vaginal smears), usually at about the third month. But in order to show that the *identical* ration to which the males were submitted would produce this pathognomonic sign of A deficiency in females an equal number of females—12 litter mate sisters of the males employed—were reared on this ration. The sisters began to show A impairment (prolonged cornified cell vaginal smears) at the 90th day, though by the end of the eighth month their fertility was as yet unimpaired. The males at this time were without impairment of fertility or either customary sign of A deficiency (xerophthalmia or growth impairment). It now appeared to us as certain that the amount of A conveyed in the wheat germ oil was too much to lead us to expect A impairment in the earlier or vigorous period of the animal's life. We consequently sought to precipitate A impairment by the entire withdrawal of wheat germ oil which, we argued, would have led to extensive storage of E but surely slighter storage of A. The wheat germ oil was accordingly stopped in the case of both groups of males (those receiving cod liver oil and those without this) and in about two months the group without cod liver oil declined and at autopsy showed degeneration of the testes while the brothers from the group receiving two drops of cod liver oil daily, autopsied at the same time, showed no such testicular changes.

It might still not seem clearly proven that the testicular degeneration which followed the withdrawal of wheat germ oil in the group of males which had never received cod liver oil was due solely or chiefly to withdrawal of the A contained in the wheat germ oil. One might still consider the possibility of defective storage of E when the simultaneous inflow of A is low or defective. We regret we did not test this point directly by subsequently conveying high A to animals which had been on a low intake of vitamin A previously.

We are fortunately in the possession of facts which enable us to make a nice discrimination in the storage of vitamins A and E in growing animals. Young animals, born and nursed by mothers with normal A, store only inconsiderable amounts of it, so that if on the day of weaning they are put on an A-free regime, they begin to fail from lack of A as early as the

50th day of life. Young, born and nursed by mothers receiving normal amounts of E, store very appreciable amounts of the fertility vitamin, so that when placed on the day of weaning on an E-free regime, they remain fertile for some time. Males, for instance, regularly retain a normal seminiferous epithelium and fertility until the 90th day of life.<sup>4</sup>

These facts, ascertained repeatedly, establish the earlier appearance of A delinquency—its appearance at a time when the body stores of E are demonstrably adequate. If, in this early failure due to A, the testicular epithelium is still intact, we would be justified in regarding its final destruction as due to low F, but if, on the other hand it is already critically impaired at a time when E is known to be adequate, it would seem that we could justifiably regard its destruction as due to low A.

Accordingly a group of 24 animals whose mothers had been transferred to diet 411 and 20 drops of wheat germ oil daily on the 15th day of lactation was divided in the following manner: eight animals were fed diet 411 plus six drops of wheat germ oil daily, eight animals diet 411, and the remaining eight diet 411 plus two drops of cod liver oil daily. The growth (fig. 1) of the animals was studied and after the group receiving unsupplemented diet 411 had appreciably declined in weight the entire group was autopsied. At this time seven of the eight animals on diet 411 had xerophthalmia, while those on diet 411 and six drops of wheat germ oil showed no eye symptoms, and all but three of the group (GH7822, W7805, BH7819) were gaining weight. At autopsy one testis was fixed for histological studies and the weight of the second was determined. The testes of the animals on diet 411 were not only smaller, as we would expect, but the ratio of the weight of the testis to the body weight was lower. The complete data for the series are found in table 1.

The fresh fluid from the epididymis was studied in each case in order to determine the type and motility of sperm present, or the absence of sperm as was found in the case of all but one (W7800) of the animals receiving diet 411. The fluid from the epididymis of those animals receiving the six drops wheat germ oil contained non-motile sperm in all but two cases. One of these animals (BH7811) exhibited more marked changes, i.e., the complete absence of sperm while the second (W7799) was not so seriously affected and exhibited motile sperm. The group of animals with the supplement of cod liver oil had motile sperm in all cases.

The histological examination of the testes revealed changes which paralleled those obtained by the study of the fluid from the epididymis. The

<sup>4</sup> This unavoidable initial fertility of animals reared on an E free regime at one time constituted an embarrassment in our studies, and has doubtless even prevented some investigators from recognizing the existence of dietary sterility due to the lack of the specific vitamin E. See chapter 3, *The Antisterility Vitamine Fat Soluble E*—Evans, H. M. and Burr, G. O. *Memoirs of the University of California*, Vol. 8.

TABLE 1

Showing testicular degeneration in young (60-72 day old) rats due to low A in the period when their initial stores of E are adequate

DESIGNATION OF ANIMAL	AGE AT AUTOPSY	INCIDENCE OF XEROPHTHALMIA	BODY WEIGHT AT AUTOPSY	WEIGHT OF ONE TESTIS	WEIGHT OF TESTIS PER 100 GRAMS OF BODY WEIGHT	OBSERVATION OF FLUID FROM EPIDIDYMS	HISTOLOGICAL FINDINGS IN THE TESTIS
Diet 411 (Devoid of conveyed A or E)							
B7809	72	-	120	0.40	0.33	No sperm	Partial degeneration. Some tubules still have spermatozoa many of which look abnormal. Most of tubules definitely degenerated though all still possess some cells
BH7806	72	+	96	0.25	0.26	No sperm	
W7800	60	+	138	0.60	0.43	Some motile sperm; others non-motile	
GH7797	64	+	100	0.60	0.60	No sperm	Every tubule greatly degenerated. (A few cells left)
W7791	65	+	96	0.20	0.20	No sperm	Every tubule greatly degenerated. (A few cells left)
GH7817	64	+	88	0.25	0.28	No sperm	
G7820	64	+	66	0.16	0.24	No sperm	
B7788	65	+	118	0.45	0.38	No sperm	
Average.....			103	0.36	0.34		
Diet 411 and 6 drops wheat germ oil daily (High E low A)							
GH7822	71	-	96	0.45	0.46	Non-motile sperm	A few tubules look normal—others partially degenerated
BH7811	72	-	79	0.20	0.25	No sperm	Some degeneration—a few tubules looked normal, many have fair number of cells left, a few are almost completely gone
W7799	72	-	160	0.65	0.40	Motile sperm	
B7808	72	-	120	0.35	0.29	Only a few non-motile sperm	All tubules partially degenerated
W7790	72	-	182	0.60	0.33	Fused sperm	

TABLE 1—*Concluded*

DESIGNATION OF ANIMAL	AGE AT AUTOPSY	INCIDENCE OF XEROPHTHALMIA	BODY WEIGHT AT AUTOPSY	WEIGHT OF ONE TESTIS	WEIGHT OF TESTIS PER 100 GRAMS OF BODY WEIGHT	OBSERVATION OF FLUID FROM EPIDIDYMIS	HISTOLOGICAL FINDINGS IN THE TESTES
<i>Diet 411 and 6 drops wheat germ oil daily (High E low A)—Concluded</i>							
	<i>days</i>		<i>grams</i>	<i>grams</i>	<i>grams</i>		
GH7796	71	—	150	0.90	0.60	Few motile sperm; others non-motile	About $\frac{1}{3}$ tubules look normal, others partially and a few completely degenerated
W7805	72	—	108	0.50	0.46	Few feebly motile sperm; others non-motile	
BH7819	71	—	138	0.70	0.51	Few non-motile sperm	
Average.....			129	0.54	0.41		
<i>Diet 411 and 2 drops cod liver oil daily (High A, no conveyed E)</i>							
BH7807	72	—	126	0.90	0.71	Motile sperm	Normal
BH7818	71	—	136	1.10	0.81	Motile sperm	
G7795	72	—	206	1.30	0.63	Motile sperm	Normal
BH7810	72	—	184	1.50	0.82	Motile sperm	Normal
W7804	72	—	140	1.20	0.85	Motile sperm	
B7789	72	—	200	1.10	0.55	Motile sperm	
GH7798	72	—	232	1.40	0.60	Motile sperm	Partial degeneration
GH7821	71	—	126	0.70	0.55	Motile sperm	
Average.....			168	1.15	0.69		

testes from the group of animals receiving diet 411 showed marked degeneration, practically every tubule being involved. In a few of the tubules the germinal epithelium had completely disappeared leaving only a network of fibers in which a few Sertoli nuclei were held. The majority of the tubules retained some of the elements of the germinal epithelium. Spermatogonia and spermatocytes could be seen in many tubules but spermatozoa were rarely found.

The animals receiving the supplement of six drops of wheat germ oil possessed testes which showed some degeneration, that is, some tubules were normal and others partially degenerated. The groups of animals receiving two drops cod liver oil had normal testes in all cases.

The above series of animals fortify the finding that in growing males

the stores of vitamin A are more rapidly depleted than those of vitamin E. The animals not only showed the signs characteristic of vitamin A

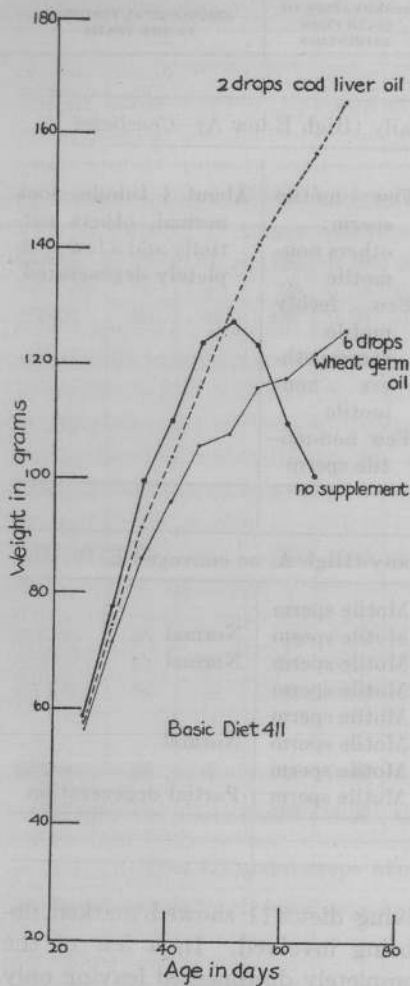


Fig. 1

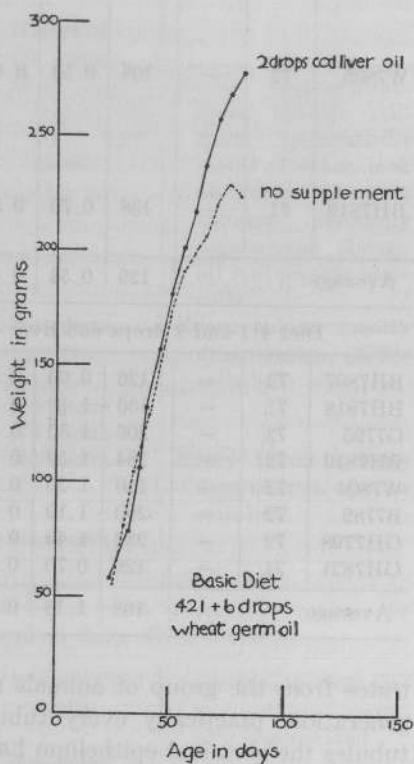


Fig. 2

Fig. 1. Each curve represents the average growth of eight male rats on diet 411 with no added vitamin A or E, with high vitamin E and low A and with low vitamin E and high A.

Fig. 2. Each curve represents the average growth of ten males on diet 421 supplemented with high vitamin E and low A in one case, and high vitamin E and high A in the second case.

deficiency—decline in weight and xerophthalmia—but the litter-mate sisters studied at the same time showed continuous cornified cells in the

vagina. The experiment seems to show conclusively that in the presence of vitamin E stored from the lactation period and with the depletion of the vitamin A stored, there is marked deterioration of the seminiferous epithelium.

The above experiments involved two extremely different situations: 1, a considerable amount of vitamin A was fed and many months passed before the animals showed decline due to low A, in fact, the decline set in only after withdrawal of A which also involved the vitamin E, and there thus entered the problem of vitamin storage of which little is known in this epoch of the animal's life: 2, the stores of vitamin A were so rapidly depleted that the animals succumbed to the deficiency before the age of sexual maturity was reached.

Accordingly, a new series of experiments was devised. Twenty males were taken at the 21st day of life and divided into two groups of 10 animals each. They were reared in individual cages on diet 421<sup>5</sup> and six drops of wheat germ oil daily. One group received two drops of cod liver oil daily, the other being without cod liver oil and therefore dependent for its vitamin A intake solely on the amount conveyed by the wheat germ oil. The average growth obtained in the two groups is illustrated in fig. 2.

The sexual activity of each animal was tested, beginning at the 50th day of life, by introducing females at estrus into the cage of the male, with examination the following morning for plug and sperm. The female was studied to determine whether a litter resulted. The advent of sterility in the male was detected by the failure of known copulations to result in pregnancy in females of proven fertility.

The inception of sterility in the group of animals reared on diet 421 and six drops wheat germ oil varied from 74 to 117 days (average 89 days). At autopsy the fresh fluid from the epididymis was studied and either abnormal sperm or no sperm were found. Histological examination of the testes revealed degeneration of the seminiferous epithelium in all cases examined. The data for the group are listed in table 2.

<sup>5</sup> The composition of diet 421 is essentially the same as diet 411 with the exceptions of the casein which is unextracted and the lard which is slightly rancid. The rancid lard is added in order to destroy any A present in the constituents of the diet. The animals receiving diet 421A supplemented with 2 drops of cod liver oil thrive very well on this diet, indicating that there are no toxic effects from the lard.

*Diet 421*

Casein (unextracted).....	25.0
Cornstarch (cooked).....	37.0
Yeast.....	8.0
Lard (slightly rancid) irradiated.....	10.0
Salt mixture # 185.....	4.0

TABLE 2  
*Showing testicular degeneration in rats due to low A at the inception of sexual maturity*  
 Diet 421 with 6 drops wheat germ oil daily

DESIGNATION OF ANIMAL	NUMBER OF INSTANCES IN WHICH AN FEMALE WAS INTRODUCED INTO MALE'S CAGE	NUMBER OF COPULATIONS	NUMBER OF LIVERS SHED	LAST FERTILE MATING (AGE IN DAYS)	FIRST STERILE MATING (AGE IN DAYS)	AUTOPSY (AGE IN DAYS)	INJURY TO TESTES (AGE IN DAYS)	BODY WEIGHT AT AUTOPSY	WEIGHT OF TESTES (GRAMS)	WEIGHT OF EPIDIDYMS	OBSERVATION OF FLUID FROM EPIDIDYMS	HISTOLOGICAL FINDINGS IN THE TESTES
BH6594	4	2	2	82	None	90	+	228	1.20	0.52	Motile sperm	Tubules appear normal
W6617	3	1	1	74	None	80	-	200	1.10	0.55	Motile sperm	
GH6628	2	2	2	82	None	87	+	214	1.32	0.61	A few non-motile sperm	Marked degeneration; no normal tubules
W6634	7	6	3	85	106	159	+	286*	0.55	0.19	Non-motile fused sperm	
W6666	10	5	3	94	105	159	-	224	0.90	0.40	No sperm	Most tubules completely degenerated; a few normal
GH6585	11	7	4	117	154	160	-	206**	1.15	0.38	Motile sperm	
BH4314	9	3	2	92	None	112	+	172	0.47	0.27	Motile sperm	
BH6636	3	0	0	0	None	Died at 74 days						
G6582	10	5	3	88	112	Died at 127 days***						
W6584	Died at 67 days											

\* At 95 days of age W6634 began to lose weight rapidly. Two drops of cod liver oil were fed on 2 successive days, growth was rapidly resumed.

\*\* GH6585 was losing weight at 91 days of age—Two drops of cod liver oil were fed on 3 successive days—there was immediate resumption of growth.

\*\*\* G6582 was losing weight at 94 days of age and was given 2 drops of cod liver oil on two successive days—growth was resumed at once.

The group of animals receiving cod liver oil was tested in the same manner as their littermate brothers. The fertility of the male was not impaired and at autopsy the findings indicated normal conditions. The complete data can be found in table 3.

These experiments seem to demonstrate clearly that the destruction of the seminiferous epithelium in the animals receiving six drops of wheat germ oil daily but without cod liver oil, was due to a deficient intake of vitamin A. That the E in six drops of wheat germ oil was adequate would appear to have been conclusively shown by the retention of normality in all animals of the group receiving the same amount of wheat

TABLE 3

Showing testicular normality when the diet is identical with that employed in table 2 but with addition of cod liver oil

Diet 421 with 6 drops wheat germ oil and 2 drops cod liver oil daily

DESIGNATION OF ANIMAL	NUMBER OF INSTANCES IN WHICH AN ESTROUS FEMALE WAS INTRODUCED INTO MALE'S CAGE	NUMBER OF COPULATIONS	NUMBER OF LITTERS Sired	AGE AT TERMINATION OF EXPERIMENT	BODY WEIGHT AT TERMINATION OF EXPERIMENT	WEIGHT OF TESTIS	OBSERVATIONS OF FLUID FROM EPIDIDYMS	HISTOLOGICAL FINDINGS IN THE TESTIS
				days	grams	grams		
B6593	8	3	3	161	360			
B6592	6	4	4	161	412			
GH6583	8	6	6	161	372			
BH6667	12	4	4	159	363	1.75	Motile sperm	Normal
W6635	7	6	6	160	406	1.60	Motile sperm	Normal
GH6629	5	5	5	161	385			
W6618	5	5	5	160	354	1.65	Motile sperm	Normal
W6665	10	3	3	161	358			
GH4315	6	5	5	160	364			
BH6586	9	5	4	160	420	1.60	Motile sperm	Normal

germ oil but with two drops of cod liver oil, a substance known to contain no E.

That the decline of the first group of animals was due to deficient A was shown by: 1, the characteristic signs of A deficiency appearing in some of them (xerophthalmia in four instances out of ten) and appearing in all cases in a group of sister animals receiving the same ration (continuous cornified cell vaginal smear at the beginning of the 50th day of life); 2, when rapid decline in weight began, a few drops of cod liver oil led to immediate resumption of growth, which lasted from twenty to sixty days (GH6634, G6582).

## SUMMARY

1. The vitamin A stored during the intra-uterine and suckling life of the rat is more rapidly depleted than the vitamin E.

2. Males maintained on diets adequate in vitamin E and low in vitamin A (the amount contained in 6 drops wheat germ oil) become sterile by the third month of life, though when entirely without E and with adequate A, sterility does not supervene until later.

3. Examination of the fresh fluid from the epididymis and histological examination of the testes indicate that marked degeneration of the testes had taken place in the absence of vitamin A and in the presence of adequate vitamin E.

55912



