




NECROTIC ŒDEMA OF THE GALL BLADDER

ANDREW STEWART LOBINGIER, M.D., F.A.C.S., Los Angeles, California



Reprint from
SURGERY, GYNECOLOGY AND OBSTETRICS
September, 1931, Vol. LIII, 395-399

Copyright, 1931, by Surgical Pub. Co. of Chicago



NECROTIC ŒDEMA OF THE GALL BLADDER

ANDREW STEWART LOBINGER, M.D., F.A.C.S., LOS ANGELES, CALIFORNIA

A STUDY of the arterial blood supply to the gall bladder discloses variations in the distribution of the cystic artery which may account for many vagaries in the pathology of the cystic duct and gall bladder. Branches from the hepatic artery pass to the cystic duct before the cystic artery supplying the gall bladder divides into two or three main stems and splits up into its terminal distribution. The venous distribution is less subject to eccentric placement and empties its main stems directly into the right stem of the hepatic vein. The vascular arrangement may be greatly modified by variations, to which the cystic duct is also subject in its relation to the choledochus and the lower portion of the common hepatic duct. These anatomic eccentricities have long been noted and described.

Of even greater significance in œdema from infection is the rich lymphatic arrangement. Sudler's illuminating investigation of the lymphatic distribution to the liver, gall bladder, and pancreas furnished the key to the epochal researches of Graham and Peterman which followed later. Extended reports on these laboratory studies on the lower animals and at the operating table on the human subject suffering from cholecystitis and hepatitis have been widely published. They are now generally accepted by surgeons whose clinical experience in gall bladder disease justifies an authoritative opinion.

Any severe infection of the liver, gall bladder, or pancreas of hæmatogenous or lymphogenous origin is always followed by an œdema. The intensity of this œdema, by which is meant the degree of destructive change in the cells of the tissues involved, will designate its nomenclature.

In our early studies of septic gall bladders little effort was made to differentiate these classifications based on any rational analysis of the pathogenesis which might be back of terminal conditions found at operation or autopsy.

They were classed as acute cholecystitis, cholangitis, empyema, cholelithiasis, gangrene, and hydrops, as the major divisions in this pathology.

When it became known that obstruction of the cystic duct resulted in infection of the mucosa and bile content in the gall bladder, and that as long as this duct was patent infection could not be produced experimentally, we were afforded a basis on which a truer scientific classification could be worked out.

We were meeting from time to time examples of infection in which an intense œdema with mottled discoloration and great enlargement of the gall bladder showed positive blocking of the blood and lymph vessels. Sometimes these gall bladders would be empty or contain gas only and the serous surface would be streaked, instead of mottled, with areas which appeared to have only a partially arrested circulation. In all of these cases the gall bladder would be found covered in with more or less extensive omental adhesions, in which the omentum shared in the œdema, with enlarged blood vessels. In several cases, somewhat more advanced in œdematous change, pools of dark, purulent fluid would be found within the omental folds about the gall bladder. When the gall bladder was opened invariably we would find a single stone, or a cluster of impacted stones, firmly fixed in the cystic duct.

Rarely if ever was there found more than from a few drops to a drachm of purulent fluid within the gall bladder. Sometimes this was mixed with bile pigment; in 3 cases there was gas only; one of these had an emphysematous wall and two of them were accompanied with marked œdema of the pancreas and beginning fat necrosis. It was obvious that such destructive pathology could be accounted for only by grave interference with the circulation, coupled with an intensely active infection. The firmly impacted stone in the cystic duct could not wholly account for this degree of pathology for, as will be later noted, this is, or has been, always present in hydrops, in which there persist no infective phenomena.

We must likewise exclude that type of septic cholecystitis which involves inflammation of the mucosa with collection and retention of pus, while the cystic duct remains transiently obstructed. In this condition the muscular and serous layers of the gall bladder are free from œdema or serious pathological change.

We felt we were dealing with an intense parenchymatous change in the entire wall of the gall bladder, due to an infection of high potency, plus a positive intraductal pressure; and that this destructive process, though it might vary in degree and extent, if not arrested by operation was destined to progress to complete destruction of the organ.

Because it is not a terminal pathological condition; because it is usually diagnosed in the

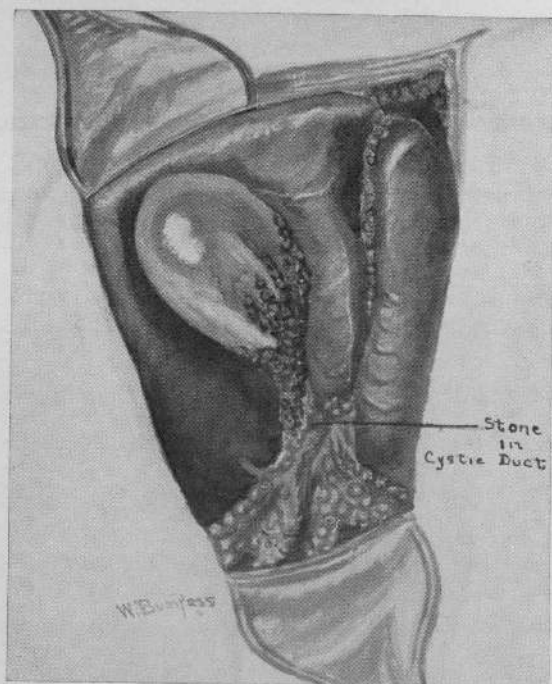


Fig. 1.

state of intense oedema with islands of pre-necrotic change, in a contribution published in 1919 and again in more specific detail in 1924 in the *California State Journal of Medicine*, we gave it the name of necrotic oedema.

The bacterial flora as shown by Rosenow and Wilkie and confirmed by Nickel and Judd, are pathogenic in the acute infections, and consist chiefly of staphylococci, bacillus coli, and the streptococcus viridans or some form of the green-producing streptococci and also certain gram-negative bacilli. These infections arise from remote foci as the appendix, apical abscesses of the teeth, follicular tonsillitis, prostatitis, sinusitis, salpingitis, endocervicitis, and as was years ago shown by Cushing, from typhoid infection of Peyer's glands.

The symptoms are pain and tenderness, with rigid rectus and a palpable mass in the region of the gall bladder. There is rarely cholæmia. The blood examination shows a leucocyte count of 20,000 to 30,000 with a polymorphonuclear count above 85. The temperature may be from 100 degrees F. to 102 degrees F; the pulse 80 to 100. If seen early the patient does not show evidences of a serious infection. We have seen a number of cases in which the high leucocyte count seemed quite out of proportion to the tempera-

ture and pulse, the former being 30,000 or over and the temperature 99.5 degrees F. to 100 degrees F., with a pulse of 80 to 90. It is to be differentiated from acute cholecystitis which may not require operative interference, by a lower leucocyte and polymorphonuclear count and absence of a dense mass in the region of the gall bladder in acute cholecystitis. There is usually a protracted history of gall bladder colic with attendant disability and confinement to bed. Associated with this paroxysmal pain there may be rigor and vomiting.

The diagnosis does not wait on laboratory findings beyond blood and urine analyses. The clinical picture is clear and sharp and to anyone who has once observed a case, is typical of the acute abdomen. It is to be noted that in all cases the liver and very frequently the pancreas, shares in the oedema, the liver especially in a zone several centimeters peripheral to the attachment of the gall bladder showing a granular, turgid surface and markedly thickened border.

The treatment is early cholecystectomy with drainage.

The author's first case of necrotic oedema of the gall bladder was in a patient seen through the courtesy of another physician in March, 1906. There were such outstanding pathological features in the case—features which now 24 years later are so typically classical for necrotic oedema—that even at that day were believed to be worthy of record. The case was reported in the *Annals of Surgery* July, 1908, and is now believed of such historic and pathologic interest as to justify its recital here:

CASE. F. J., Teuton, age 55, married, was first seen February 26, 1906, by my assistant, Dr. Paul Adams, who called me to examine the patient.

The family history was negative. Until recently he had been a resident of Brooklyn, New York. Up to 5 years ago he had been a hard drinker, chiefly of whiskey. On October 15, November 15, and November 29, 1905, he had suffered severe attacks of pain in the region of the gall bladder. These attacks which were supposed to be gall-stone colic, developed and disappeared very suddenly and left the patient prostrated. Jaundice more or less persistent had been present for more than 3 years. Early in the history of the patient he was said to have sugar in the urine and an excess of urea.

When first called, Dr. Adams found the patient suffering severe pain in the region of the gall bladder. These pains radiated downward as well as upward toward the right scapula. The liver was somewhat enlarged extending an inch below the costal border. There was marked tenderness on light pressure over the gall bladder. The heart showed a moderate systolic murmur. There was a well developed jaundice, and bile and a trace of albumin were found in the urine. At this time the temperature was normal and the pulse 90, but the patient felt sure the pain he was suffering was more severe than in any previous attack.

I was called in by Dr. Adams on March 1. The patient was a large plethoric subject with jaundiced skin and conjunctivæ. His temperature was then 102.4 degrees F. and the pulse 118, and he had had several rigors. He complained of a severe pain in the right hypochondrium, which extended through to the back. The right rectus was rigid and there was a dense mass in the region of the gall bladder, which was only slightly tender on firm pressure. The diagnosis was suppurative cholecystitis with localized peritonitis, and immediate operation was advised. The operation was at the California Hospital on March 2.

The gall bladder which was several times the normal size, was gangrenous and distended with gas. It was covered in and walled off from the peritoneal cavity by the gastrohepatic and a portion of the great omentum. Surrounding the base of the gall bladder was a pool of dark, slate colored, purulent fluid. The omentum was deeply injected and stained by this dark fluid. The fluid was sponged away and the gall bladder opened. It contained gas only; the walls were moist and were distinctly emphysematous, crackling under pressure between the thumb and finger. The mucosa easily separated from the wall and both were gangrenous.

In the upper portion of the cystic duct was an irregular stone about the size of a small hazelnut, imbedded in sand and gravel like millet seeds. No other concretions were found. The common and hepatic ducts were probed and found clear. The gall bladder was freed of further adhesions and removed, a drain being placed in the remaining portion of the cystic duct. A pocket above and one below the former position of the gall bladder were drained with cigarette drains. The convalescence was not marked by any unusual incident and the patient left the hospital March 16. A slight mucous discharge continued for several weeks from the drainage fistula.

The feature of especial interest in this case is the emphysematous condition of the gall bladder wall and the distention with gas of the bladder itself. Of the bacterial flora present little can be said, as the material taken for smear and culture was accidentally destroyed. One might assume the presence of coli, probably the commonest form of gas producing bacillus incident to the gall bladder.

In this report of a patient operated on almost a quarter of a century ago for what was then diagnosed as gangrene of the gall bladder, we were conforming to the classification current in the surgical literature of the time. Up to the time of this report and until some years later, we had not seen a case of true gangrene of the gall bladder and had accepted the nomenclature of the authorities of that day. We have the conviction that much of the nomenclature of the pathology of the liver, gall bladder, and pancreas needs revision. Classifications more in consonance with the newer interpretation of this pathology would be of very real value to the clinical surgeon.

It is an accepted principle in pathology that all reticulo-endothelial structures take on œdema in the presence of infection, or other chemical irritation which may give rise to cloudy swelling. This œdema in the early stage may not be destructive. If the cause is removed and the patency of the blood and lymph vessels re-

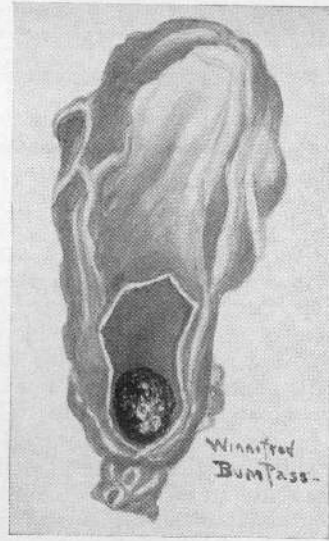


Fig. 2.

established, the œdema will subside and function be restored. In the case of the gall bladder, a branch of the cystic artery may still be patent and the portion of the gall bladder fed by it remain fairly well nourished, while in other portions the blood supply may be blocked by pressure from within the cystic duct and by the œdema which accompanies it. The œdema may be even subacute as well as partial, embracing a portion only of the viscus.

In true gangrene of the gall bladder the entire blood supply is definitely cut off and there is a corresponding block of the lymph system. The state of œdema has passed to one of absolute necrosis, and the viscus takes on a limp, moist, slate-colored aspect attenuated in texture and wholly devoid of life. The author has seen but one case of true gangrene of the gall bladder and it is a pathological picture never to be forgotten.

As long as the afferent and efferent circulatory streams are functioning, gangrene cannot occur. In most of these cases of necrotic œdema which we see there are areas in the gall bladder wall more or less normal in appearance which are still being fed by blood vessels and drained by lymph vessels. In all of these cases there are extensive adhesions between the serous coat and highly vascular folds of omentum, which have formed an anastomosis and serve to keep alive the gall bladder wall. It has been clearly demonstrated that feeder capillary shoots are also projected from the liver, when the hepatic œdema is not intense, which in like manner contribute to the

vitality of the threatened gall bladder wall. Only in those fulminating, highly infected types of œdema do these auxiliary factors in conserving the life of the gall bladder fail. The case reported in this paper is one of these and only immediate operation can arrest the progress of such a destructive change from its lethal termination in true gangrene.

Although it is too hazardous to predicate a justification for delay in operating upon these patients, it is certain that some of them do recover without operation, as contracted gall bladders abundantly testify. No gall bladder ever can contract down to half or third its normal size, as we frequently see, without a definite substantive inflammatory change having taken place antecedent to this contraction. A carefully taken anamnesis will invariably disclose the history of one or many acute attacks of cholecystitis with a typical syndrome of cholelithiasis infectiva. These are cases not of so called empyema—pus in the gall bladder with an infected mucosa—they are cases of infection of all the layers of the gall bladder wall, but in which there is sufficient blood supply remaining to save the viscus from entirely perishing. The stone which obstructs the cystic duct, and by its transitory pressure blocks the blood and lymph stream, is not so firmly impacted, but in time it will work its way back into the antrum of the gall bladder and the pressure obstruction of the vessels is then relieved. Through the repetition of these attacks, the oft repeated inflammatory seizures cause the wall in time to contract down on the imprisoned stones to a size less than one-half the normal.

A very different clinical picture obtains in septic cholecystitis with pus in the gall bladder. This may be, and frequently is, a transitory phase of partial obstruction of the cystic duct with the usual sequence—which, Peterman's experiments proved with such conclusive data—the infection of the fluid contents of the gall bladder and the mucosa. The submucous reticular area, the muscular coat, and the serosa do not share in this infection, and it may and very frequently does have but a casual prognostic significance. For when the obstruction is relieved the pus drains away and the mucosa is largely restored to its normal function. At no time in this empyema was the vascularity of the gall bladder obstructed. At no time were the other coats of the wall found to be œdematous from blocking of the lymphatics. At no time was necrotic œdema or its terminal expression, true gangrene, threatened.

It is true that over a prolonged period of successive attacks of septic cholecystitis the reticular cells in time may become greatly thickened and these dense gall bladders become foci which may perpetuate a chronic hepatitis which will result in grave cirrhosis. Since Babcock's observations were published years ago we have known what a serious change in the myocardium and tax on the heart may attend these cases of hepatitis from recurrent septic cholecystitis. These are all cases demanding early extirpation of the gall bladder, preferably after subsidence of the syndrome. The destiny of most cases of this type of gall bladder, if not removed early, is hydrops.

No greater proof can be offered of the correctness of the argument in this differential pathology than the integrity, even though modified, of the mucosa in hydrops. The mucosa of the cystic gall bladder goes on secreting mucus as long as the distended wall will retain it. All of these cases give a prolonged history of successive attacks of septic cholecystitis. All of them have a thickened fibrous wall as a result of years of recurring inflammatory reactions from repeated infections and increase of connective tissue. Finally the cystic duct becomes permanently closed from stricture, the gall bladder fills with mucus and is henceforth in this terminal state, practically immune to future infection or inflammatory change.

Why does this pathological process of successive infections never terminate in necrotic œdema or in gangrene? During the prolonged process of the rise and fall of successive infections, as obstruction in the cystic duct came and went, the deposition of connective tissue was confined largely to the submucous reticulum, leaving the blood and lymph vessels substantially free from obstruction.

These infections are at no time associated with the phenomena of a fixed œdema; they are a local mucous and submucous invasion and go through none of the changes which characterize a general mural œdema.

Until it was demonstrated by a long series of experiments on laboratory animals and by observation at the operating table of the living pathology in the human subject, the phenomena in the mural and parenchymatous infections resulting in the varying degrees of œdema had remained uninterpreted.

SUMMARY

All acute and subacute infections in the liver, gall bladder, and pancreas are associated with œdema.

Infection of the gall bladder is a transitory invasion confined to the mucosa and submucosa as long as the blood and lymph supply are not definitely blocked.


Necrotic oedema is a definite pathological condition in the gall bladder and cystic duct due to a more or less complete blocking of the blood and lymph stream from infection, and from obstruction of the cystic duct. It is characterized by a peculiar symptomatology and blood picture and

by destructive changes in the tissues resulting from a fixed oedema.


Septic cholecystitis, either acute or subacute, is not to be confused with this, either in symptomatology, or pathology, immediate or remote; and it has a terminal destiny in no way resembling necrotic oedema.

All persistent destructive infections of the gall bladder, not associated with pancreatitis, call for early cholecystectomy with drainage.

40788









PRINTED BY R. B. DONNELLEY & SONS CO., AT CHICAGO, ILLINOIS, U.S.A.